

DTRF Virtual Tumor Board

2017 DTRF Desmoid Tumor Research Workshop


Aaron Weiss, DO

Associate Professor of Pediatrics


Tufts University Medical School

Pediatric Hematology-Oncology

Maine Children's Cancer Program




Definition




- Multidisciplinary treatment planning approach for reviewing and discussing the medical condition and treatment options of a patient

Background




- No standardized approach to upfront, progressive or recurrent desmoid tumor management
- Opinions of “experts” frequently sought
- Advice often given with limited information regarding the case

Purpose




Creation of an established scientific forum for discussion of complex desmoid tumor cases

Planning



- Small working group discussions
 - Surgical oncology
 - Radiology
 - Pathology
 - Medical oncology
 - Pediatric oncology
 - Informatics

Sponsorship




- Desmoid Tumor Research Foundation

Format




- Regularly scheduled meetings
- Web-based conference platform
- Core of committed specialists

Access




- Open to medical personnel (no patients)
- Initially North America with goal of international expansion

Process




- Cases solicited ahead of meeting
- Meeting announcements
- Presenting site responsible for providing their own radiology/pathology personnel (if applicable)

Security



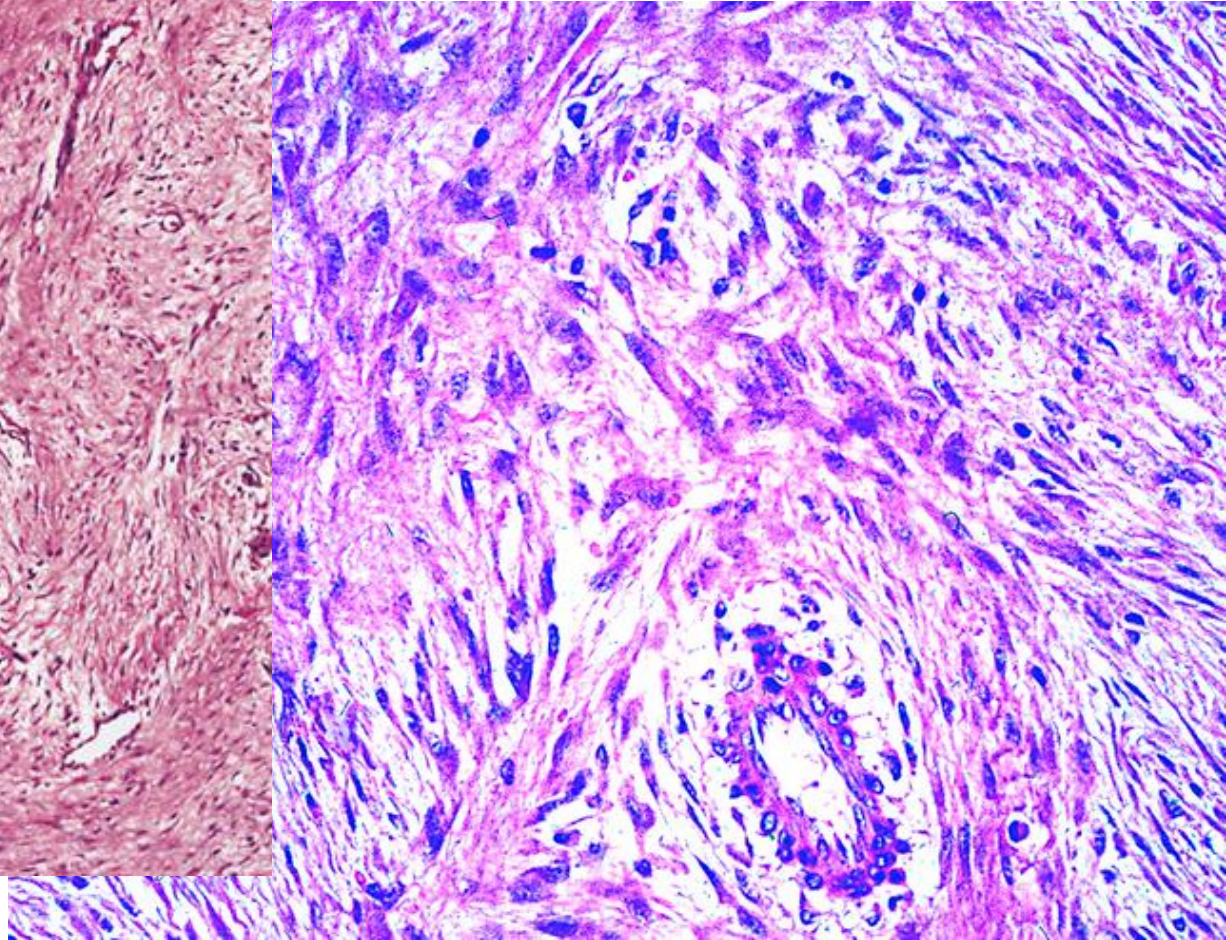
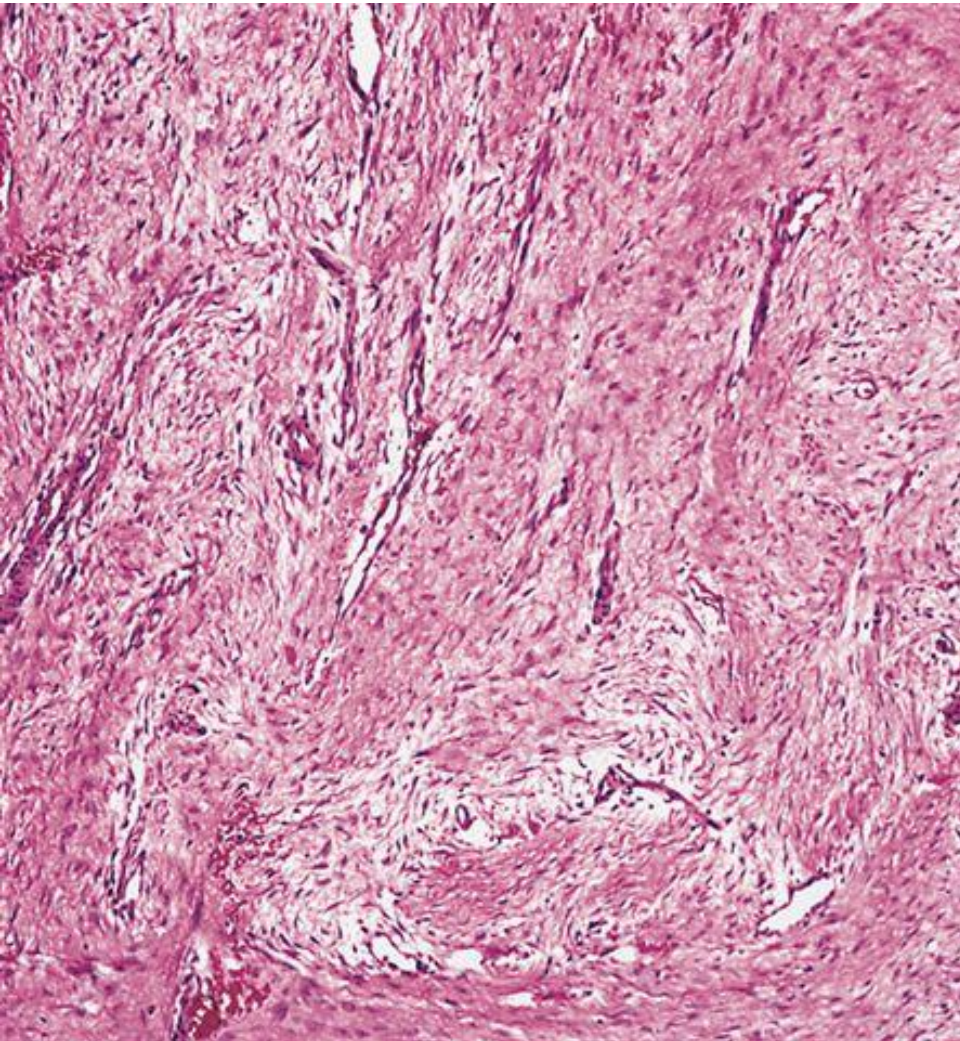

- HIPAA provisions
- Removal of Protected Health Information (PHI)
- Pre-presentation site instructions

Sample Case




- 18 yo male with FAP syndrome
- Maternal history of FAP
- Underwent screening colonoscopy in 2014
- Found numerous polyps → colectomy with J-pouch
- Developed lower abdominal/back pain in Oct 2015
- Abdominal mass discovered
- Needle biopsy performed

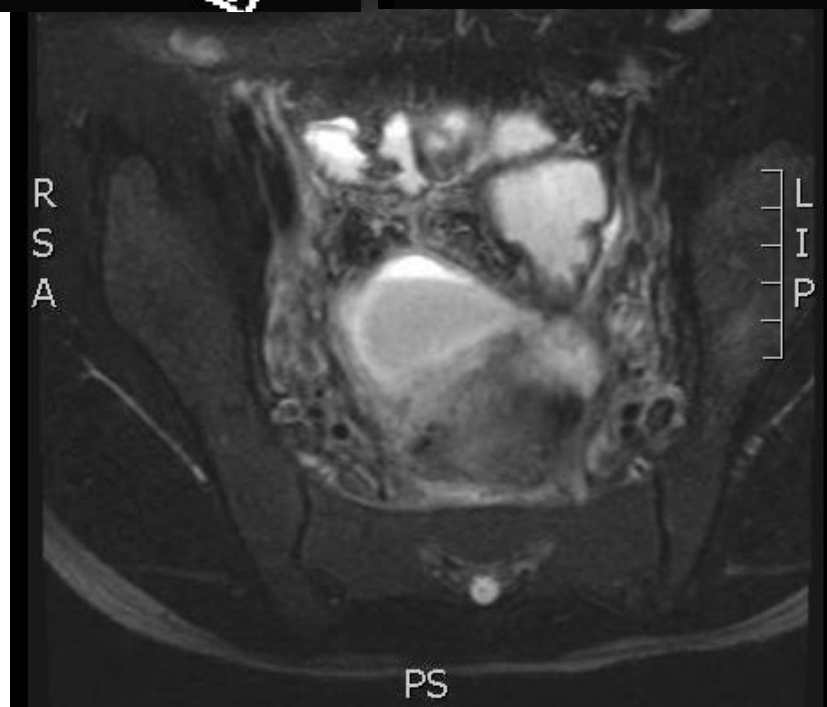
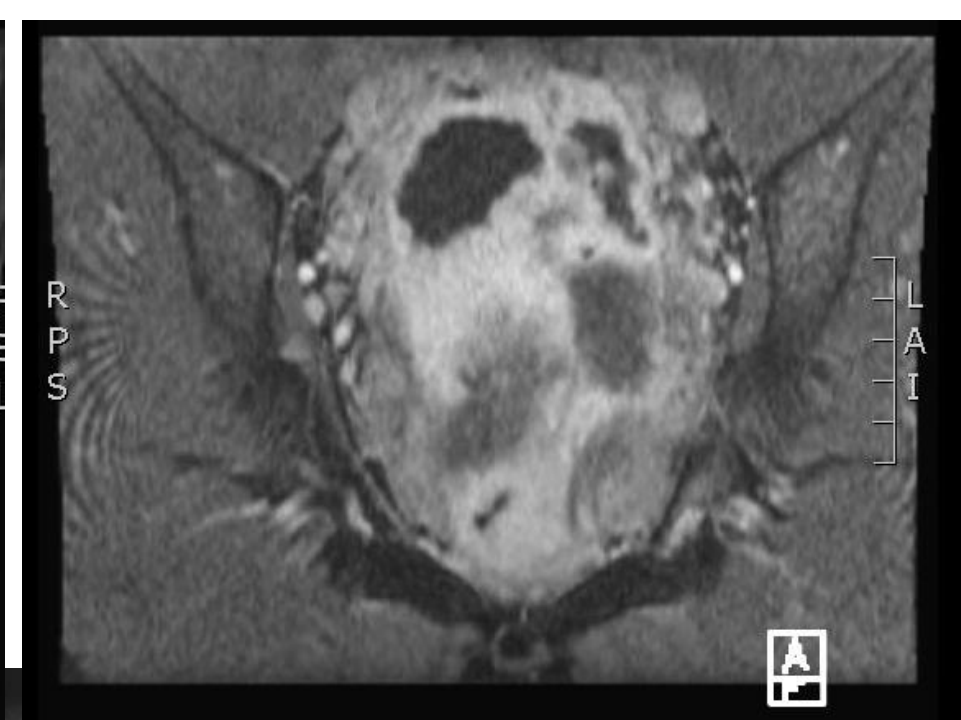
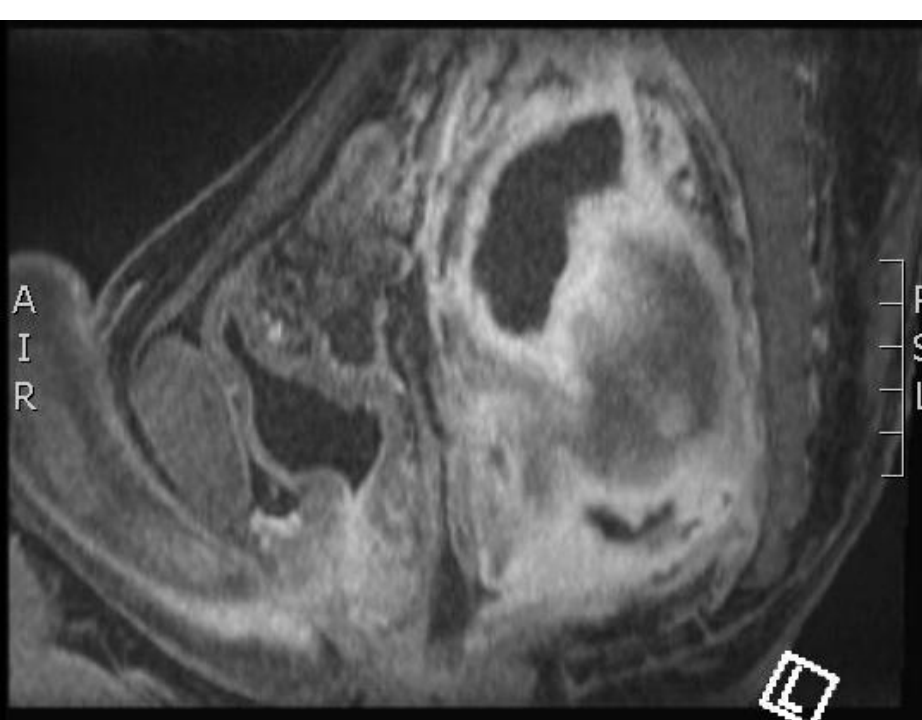
Sample Case




Sample Case



- Dec 2015: started on sorafenib
 - Mild decrease in symptoms and tumor burden
- Oct 2016: changed to tamoxifen/sulindac
- Worsening pain and new concerns of bowel encased within the tumor
 - Surgery being recommended
 - Would lead to permanent colostomy and patient reluctant




Sample Case




- Questions for the group:
- Is surgery a reasonable option as a next step?
- What other, if any, neoadjuvant or adjuvant therapies should be considered?
- Is this patient eligible for any open clinical trials?

Mission

- Multidisciplinary
- Resourceful
- Inclusive
- Collaborative




Goals




- First tumor board session: week of 12/4/17
- Targeted publicity

Acknowledgements

- Aimee Crago
- Keila Torres
- Rob Lefkowitz
- Matt van de Rijn
- Steve Attia
- Joe Earl
- Tom Ellingson
- DTRF: Marlene, Jeanne, Lynne



Interested in Participating?



weissa2@mmc.org